

Joint Mobilization: Elbow, Wrist and Hand


Emily Altman, PT, DPT, CHT, OCS, WCC, CLT

1

Special Thank You

Ann Porretto-Loehrke, PT, DPT, CHT, COMT, CMTPT

- ♥ Introduced me to the world of manual therapy
- ♥ Trained me
- ♥ Mentored me
- ♥ Shared with me
- ♥ Gave me opportunities
- ♥ Measurably impacted my practice and helped my patients



2

About Me

- ▶ Product of my mentors
- ▶ Ann Poretto-Loerkhe
 - ▶ "It is the missing piece"
- ▶ IAOM-US Upper Extremity Track
- ▶ Also taken
 - ▶ University of St. Augustine (Paris),
 - ▶ Brian Mulligan
 - ▶ Geoffrey Maitland
 - ▶ Robin McKenzie

3



Logos include: IAOM, AAOMPT, NAIMT (The North American Institute of Orthopedic Manual Therapy), Maitland Australian Approach, Ola Grimsby, IPA (Institute of Physical Art), Evidence In Motion, MULLIGAN Manual Therapy Concept, THE MCKENZIE INSTITUTE USA, UNIVERSITY OF ST. AUGUSTINE FOR HEALTH SCIENCES, and IOMT (Kaltenborn-Evjenth OMT).

4

History of Manual Therapy

- ▶ Dates back thousands of years
- ▶ Is owned by no one
- ▶ Involves the use of your hands to **diagnose** and treat joint and soft tissue "lesions"
- ▶ Same concepts can be used by different disciplines
 - ▶ Osteopaths (DO)
 - ▶ Chiropractors
 - ▶ MD
 - ▶ Physical Therapists
 - ▶ Occupational Therapist
 - ▶ Others
- ▶ Scope of practice limitations for certain techniques
- ▶ Used in conjunction with other techniques

5

History of Manual Therapy

- ▶ Hippocrates (460-385 BCE)
- ▶ Ancient Romans
 - ▶ Claudius Galen (131-202 CE)
- ▶ Baghdad
 - ▶ Avicenna (CE 980-1037)
- ▶ Widespread Manual Therapy Begins in the 19th Century

A History of Manipulative Therapy

Erland Pettman, PT, MCSP, MCPA, FCAMT, COMT

The Journal of Manual & Manipulative Therapy
Vol. 15 No. 3 (2007), 165-174

6

Names Like....

Earlier...	Later....
▶ Andrew Still (b 1828)	▶ Freddy Kaltenborn
▶ Daniel Palmer (b 1845)	▶ Robin McKenzie
▶ James Mennell	▶ Ronald Stensnes
▶ Edgar Cyriax	▶ Brian Mulligan
▶ John Mennell	▶ Stanley Paris
▶ James Cyriax	▶ Geoffrey Maitland

7

Fuzzy Domains/Terminology

- ▶ Joints
- ▶ Soft tissue
 - ▶ Capsule
 - ▶ Ligaments
 - ▶ Tendons
 - ▶ Fascia
 - ▶ Muscles
- ▶ Manipulation
- ▶ Mobilization

8

James Cyriax

- ▶ British doctor
- ▶ 1904-1985
- ▶ “Father of orthopedic medicine”
- ▶ System of clinical exams to diagnose and treat soft tissue lesions
 - ▶ Active and resisted motion
 - ▶ Passive movement
 - ▶ Capsular pattern
 - ▶ Non capsular pattern
- ▶ Find the source of pain

9

Evaluation

- ▶ Systematic
- ▶ Results lead to
 - ▶ Musculoskeletal diagnosis
 - ▶ Treatment interventions
- ▶ Mobilization techniques shouldn't be thought of in isolation.

10

Cyriax Textbook of Orthopaedic Medicine

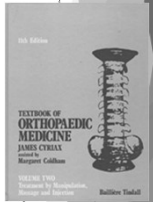
“Routine physiotherapy forms no part of the practice of orthopaedic medicine. The individual approach that this discipline entails therefore makes unwonted [=unusual, ≠ unwanted] demands on the physiotherapist. She cannot skim over the surface; for she knows that, within this sphere, a specific treatment exists for nearly every lesion. She cannot allow herself imprecise measures even if the doctor refers the patient with an inexact request. To this end, she assesses the function of in turn of every tissue that could be relevant to the symptoms present. She singles out the structure at fault, and which part of it, and selects the individually correct treatment. This intellectual approach involves thought, a clear concept of applied and functional anatomy, and never-failing interest and care. It also requires conscientious expenditure of time and trouble on a scale hardly known in other physiotherapeutic disciplines.”

Progress and adjust interventions as tissues indicate.
Makes up her own mind when to call a halt.

“I hope to make it clear that in orthopaedic medicine, the physiotherapist's judgment and help reach far beyond that of a mere technician. She is a most valuable, indispensable member of the team. She makes many decisions, all based on informed clinical assessments”

11

- ▶ No skimming the surface
- ▶ Specific treatment
- ▶ No imprecise evaluations/assessments (even in the face of imprecise referrals)
- ▶ Function of all involved tissues
- ▶ Determine structure at fault
- ▶ Select correct treatment
- ▶ Intellectual approach
 - ▶ Thought
 - ▶ Knowledge of applied, functional anatomy
 - ▶ Never failing interest
 - ▶ Conscientious expenditure of time
- ▶ Not a technician
- ▶ Make decisions based on informed clinical assessments



12

Plan for Today

- ▶ Introduction to evaluations of the elbow, wrist and hand
 - ▶ Emphasis on bony elements
- ▶ My favorite joint mobilization techniques for elbow, wrist and hand
- ▶ Short time to palpate and practice and ask questions/discuss

13

Concept of Capsular vs Non-Capsular Patterns of Joints

- ▶ Capsular pattern of restriction is a limitation of pain and movement in a joint specific ratio, usually present with arthritis or following prolonged immobilization.
 - ▶ Glenohumeral joint: ER>Abd>IR
- ▶ Non-Capsular pattern
 - ▶ Extra articular lesion, loose body

14

Joint End Feel

- ▶ Boggy
- ▶ Firm
- ▶ Hard
- ▶ Soft
- ▶ Capsuloligamentous
- ▶ Elastic
- ▶ Bony
- ▶ Empty

15

Technique Descriptors

- ▶ Traction/Distracton
- ▶ Glides
 - ▶ Force is parallel to treatment plane
- ▶ Curved Glides
- ▶ Oscillation
- ▶ Static Hold

16

Convex Concave Rule

- ▶ When the convex moves on the concave, roll and glide are in the opposite direction
- ▶ When the concave moves on the convex, roll and glide are in the same direction

17

Indications

- ▶ Joint hypomobility
- ▶ Pain

18

General Concepts

- ▶ Force applied parallel to the treatment plane

Distraction will be perpendicular

19

General Concepts

- ▶ Often perform mobilizations in loose packed position
 - ▶ There are exceptions!
- ▶ Mobilize in the direction of the loss of motion
- ▶ Patient/body part position
 - ▶ As close to joint as possible
 - ▶ Good body mechanics
 - ▶ Efficient, direct (often 90 degrees) force application

20

Tools

OPTP.com

21

The Elbow-Surface Anatomy

- Palpate
 - ▶ Supracondylar Ridge
 - ▶ Lateral Epicondyle
 - ▶ Olecranon
 - ▶ Radial Head
 - ▶ Medial Epicondyle

22

The Elbow-Bony Anatomy/Architecture

- ▶ 4 articulations to consider
 - ▶ Ulnohumeral
 - ▶ Proximal radioulnar
 - ▶ Radiohumeral
 - ▶ Distal radioulnar

Image Courtesy of IAOM-US. www.iaom-us.com

23

Humeral Trochlea

Medial & lateral glide direction: 60° from a line connecting the epicondyles

Slide Courtesy of and Property of IAOM-US. www.iaom-us.com

24

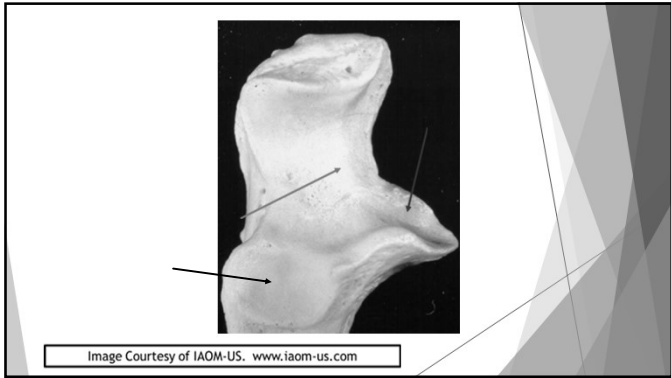


Image Courtesy of IAOM-US. www.iaom-us.com

25

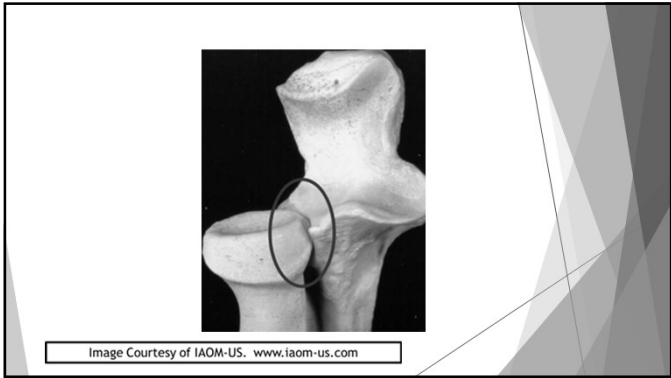


Image Courtesy of IAOM-US. www.iaom-us.com

26

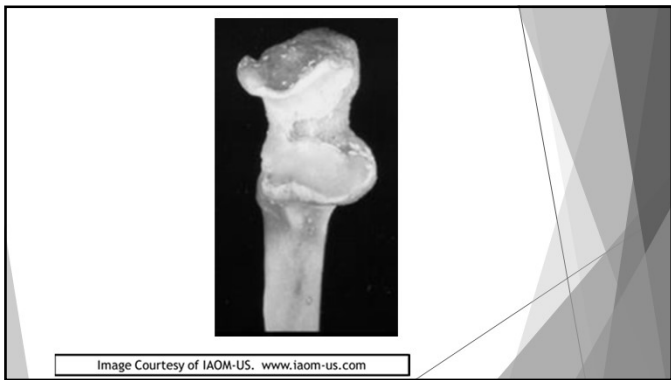

Image Courtesy of IAOM-US. www.iaom-us.com

27

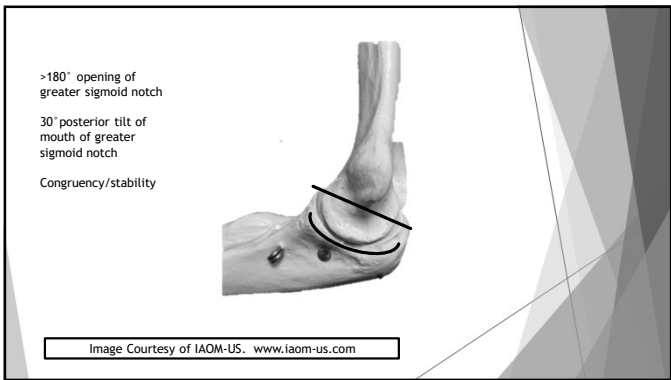
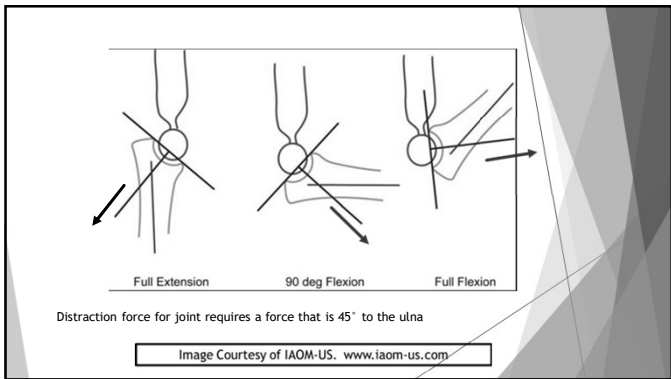


Image Courtesy of IAOM-US. www.iaom-us.com

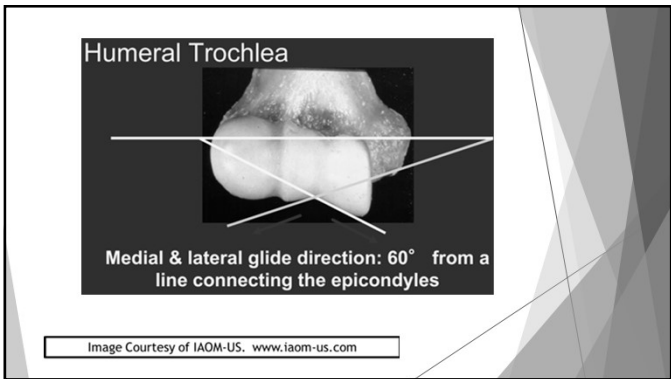
28



Distraction force for joint requires a force that is 45° to the ulna

Image Courtesy of IAOM-US. www.iaom-us.com

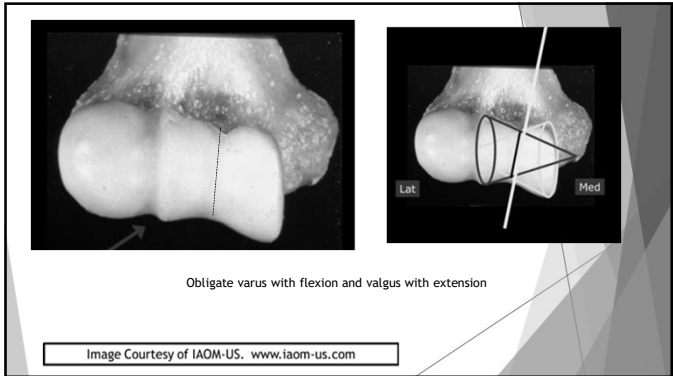
29



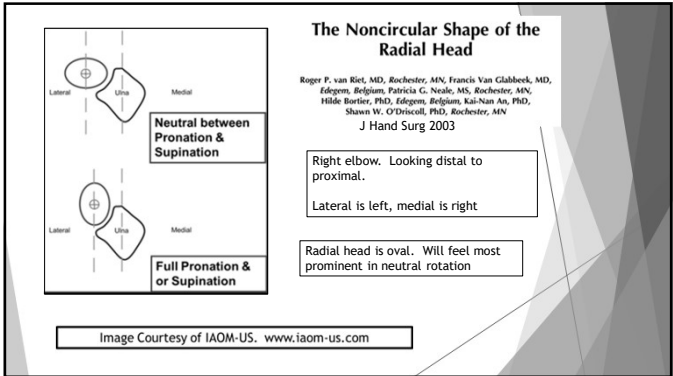
Humeral Trochlea
Medial & lateral glide direction: 60° from a line connecting the epicondyles

Image Courtesy of IAOM-US. www.iaom-us.com

30



31



32

Odd Bits: Elbow

- ▶ Pain Reference
 - ▶ Pain is where the painful structure is!
- ▶ Functional Coupling
 - ▶ Flexion + Supination
 - ▶ Extension + Pronation

33

Ulnohumeral Joint

- ▶ Maximal loose packed position
 - ▶ 70 Flexion
 - ▶ 10 Supination
- ▶ Maximal close packed position
 - ▶ 0 Flexion
 - ▶ Maximum Supination

Open packed position: contact between articulating surfaces is minimal. Capsule, ligaments relatively relaxed. Greatest amount of joint play. Usually near mid-range

Close packed (closed-packed) position: position of maximum congruency of the articular surfaces.

34

Radiohumeral Joint

- ▶ Maximal loose packed position
 - ▶ 0 Flexion
 - ▶ Maximal Supination
- ▶ Maximal close packed position
 - ▶ 90 Flexion
 - ▶ 0 Supination

35

Proximal Radioulnar Joint

- ▶ Maximal loose packed position
 - ▶ 70 Flexion
 - ▶ 35 Supination
- ▶ Maximal close packed position
 - ▶ Neutral forearm rotation

36

Elbow Evaluation

- ▶ History
- ▶ Inspection
- ▶ AROM
- ▶ PROM
 - ▶ Capsular pattern is flexion>extension
 - ▶ Normal end feel is hard in extension and soft in flexion
- ▶ Resistive Tests
- ▶ Special Tests (eg, instability testing)

37

Elbow Joint Mobilization Techniques

- ▶ Most appropriate for post traumatic stiffness

38

Principles of Joint Mobilization

- Always test the uninvolved side first!
- Purpose of joint mobilization: to improve capsular mobility, thereby increasing ROM
- Traction (perpendicular to joint surface): can preposition in 3 planes
- Glides (parallel to joint surface): can preposition in 2 planes
- Joint mobilizations should not be painful!

Slide Courtesy of and Property of IAOM-US. www.iaom-us.com

39

Grades of Mobilization(Maitland)

Grade I: A small amplitude movement performed at the beginning of the available range.

Grade II: A large amplitude movement performed within a *resistance-free* part of the available range.

Grade III: A large amplitude movement performed into resistance or up to the limit of the available range.

Grade IV: A small amplitude movement performed into resistance or up to the limit of the available range.

Grade V: A small amplitude high velocity general movement performed usually, but not always, at end of the available range.

Slide Courtesy of and Property of IAOM-US. www.iaom-us.com

40

Grades of Mobilization

*Small amplitude of high velocity that may be performed at any position within the range

Maitland's peripheral manipulation, ed 4. Hengeveld E. Banks K. eds. Philadelphia PA 19103, Elsevier Butterworth Heinemann, 2005.

Beginning of available range Resistance free of available range Limit of available range

Slide Courtesy of and Property of IAOM-US. www.iaom-us.com

41

Humeroulnar Joint treatment

Techniques to improve extension

• coupled motion: elbow extension and forearm pronation

Extension



Slide Courtesy of and Property of IAOM-US. www.iaom-us.com

42

HUJ treatment

Techniques to improve extension

1. apply the belt at the central aspect of the humerus

2. Wrap the belt around twice, keeping the buckle side short



Slide Courtesy of and Property of IAOM-US. www.iaom-us.com

43

HUJ treatment

Techniques to improve extension

3. Attach the the long end of the belt to the mat table, using a mobilization clip

4. Clip the ends together & place a cuff weight beneath the distal end of the humerus


Slide Courtesy of and Property of IAOM-US. www.iaom-us.com

44

HUJ treatment

Techniques to improve extension

The ideal belt position at the shoulder to prevent anterior tilting compensation ☺



Slide Courtesy of and Property of IAOM-US. www.iaom-us.com


45

HUJ treatment

Techniques to improve extension

Traction

- start in maximal loose-packed position (MLPP)
- direction of mobilization: 45° to the ulnar diaphysis



Slide Courtesy of and Property of IAOM-US. www.iaom-us.com

46

HUJ treatment


Techniques to improve extension

Traction

- can pre-position the joint in extension and forearm pronation

Can perform:

- oscillations
- static holds: 40 seconds x 6 repetitions



Slide Courtesy of and Property of IAOM-US. www.iaom-us.com


47

HUJ treatment

Techniques to improve extension

Traction

- can change hand placement with pre-positioning the joint into further extension and forearm pronation



Slide Courtesy of and Property of IAOM-US. www.iaom-us.com


48

HUJ treatment

Techniques to improve end-range extension

Curved Glide

- Apply traction to the HUJ with one hand at a 45° angle from the ulnar diaphysis
- The other hand glides the ulna in a posterior-superior direction
- Equal force is applied between the traction and posterior-superior glide



Slide Courtesy of and Property of IAOM-US. www.iaom-us.com

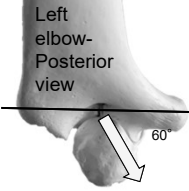
49

HUJ treatment

Techniques to improve end-range extension

Medial Glide

- direction of glide: 60° postero-medial from a line connecting both humeral epicondyles and perpendicular to the ulna
- maintain pressure on ulna (not radius)



Left elbow-Posterior view

Slide Courtesy of and Property of IAOM-US. www.iaom-us.com


50

HUJ treatment

Techniques to improve end-range extension

- place a cuff weight under the distal end of the humerus
- can pre-position the elbow in maximal extension with forearm pronation
- use heel of hand to provide 60° angle on proximal ulna

Medial Glide



Slide Courtesy of and Property of IAOM-US. www.iaom-us.com

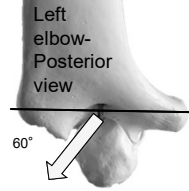
51

HUJ treatment

Techniques to improve end-range extension

Lateral Glide

- direction of glide: 60° postero-lateral from a line connecting both humeral epicondyles and perpendicular to the ulna
- maintain pressure on ulna (not radius)



Left elbow-Posterior view

Slide Courtesy of and Property of IAOM-US. www.iaom-us.com


52

HUJ treatment

Techniques to improve end-range extension

Lateral Glide

- cuff weight under distal end of the humerus
- pre-position the elbow in maximal extension with forearm pronation
- use heel of hand to provide 60° angle on proximal ulna



Slide Courtesy of and Property of IAOM-US. www.iaom-us.com


53

HUJ treatment

Techniques to improve end-range extension

Neuromuscular Reeducation

- perform repeated passive end range extension, coupled with forearm pronation, with light traction
- Move on to active assisted, followed by active and isometric of agonists, antagonists, agonists at end of new ROM.

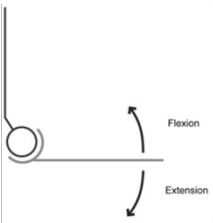


Slide Courtesy of and Property of IAOM-US. www.iaom-us.com

54

HUJ treatment

Techniques to improve flexion



Flexion

Extension

- coupled motion: elbow flexion and forearm supination

Slide Courtesy of and Property of IAOM-US. www.iaom-us.com

55

HUJ treatment

Traction



- closed chain: stabilizing the ulna, the HUJ can be mobilized by using a belt to provide a traction force to the distal humerus


Slide Courtesy of and Property of IAOM-US. www.iaom-us.com

56

HUJ treatment

Techniques to improve flexion

1. Place the patient's forearm on the mat table
2. Apply Dycem (or similar non-skid material) on the volar aspect of the distal humerus





Slide Courtesy of and Property of IAOM-US. www.iaom-us.com

57

HUJ treatment

Techniques to improve flexion

3. Place the belt around the distal humerus at a 45° angle and therapist's trunk

- oscillations or
- static holds: 40 seconds x 6 repetitions

Slide Courtesy of and Property of IAOM-US. www.iaom-us.com


58

HUJ treatment

Techniques to improve end-range flexion

- place a belt horizontally over the distal end of the humerus
- apply traction to the HUJ with both hands
- use the shoulder to lever the elbow into more flexion while applying a traction force at a 45° angle

Curved Glide




Slide Courtesy of and Property of IAOM-US. www.iaom-us.com

59

HUJ treatment

Techniques to improve end-range flexion

Neuromuscular Reeducation



- follow up with active assisted flexion, coupled with forearm supination
- move on to active motion
- than, isometric of agonists, antagonists, and agonists at the new end ROM.

Slide Courtesy of and Property of IAOM-US. www.iaom-us.com

60

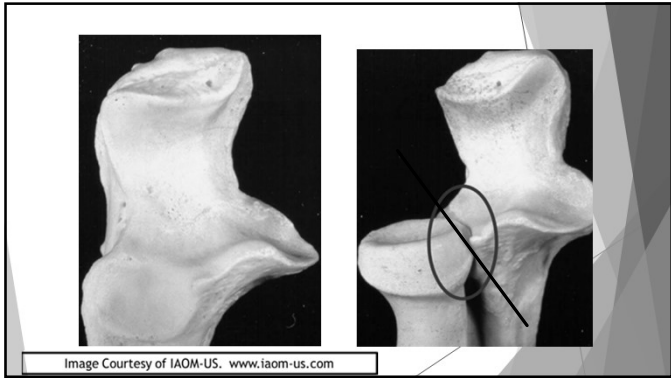


Image Courtesy of IAOM-US. www.iaom-us.com

61

Volar-medial glide of the radial head

- Assess the excursion and end-feel of this motion
- If limited, this may contribute to limitations with FA supination!

Image Courtesy of IAOM-US. www.iaom-us.com

62

Improving Supination
Volar-medial glide of the radial head

- May begin treatment in this position (maximal loose-packed position)
- 40 seconds holds x 6 repetitions

Image Courtesy of IAOM-US. www.iaom-us.com

63

PRUJ: joint specific treatment
Improving Supination

Volar-medial glide of the radial head

64

Neuro-muscular re-education
Improving Supination

65

Improving Pronation
Dorsal-lateral glide of the radial head

- To add more stretch to the PRUJ joint capsule, the patient can be pre-positioned in more pronation
- 40 second holds x 6 repetitions

Image Courtesy of IAOM-US. www.iaom-us.com

66

66

PRUJ: joint specific treatment
Improving Pronation

Dorsal-lateral glide of the radial head

67

Neuro-muscular re-education
Improving Pronation

68

PRUL/DRUL Controlling Motion

Kleinman WB. Stability of the distal radioulnar joint: biomechanics, pathophysiology, physical diagnosis, and restoration of function. What we have learned in 25 years. *J Hand Surg.* 2007;32(7):1086-1106

69

The Wrist-Surface Anatomy

Image Courtesy of IAOM-US. www.iaom-us.com

70

Surface Anatomy—volar wrist

- Follow the FCU tendon distally, until you reach the pisiform bone
- It's larger than it appears!

Slide Courtesy of and Property of IAOM-US. www.iaom-us.com

71

Surface Anatomy—volar wrist

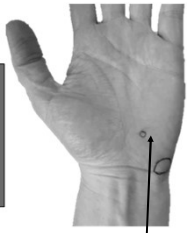
- To locate the hook of the hamate, place the IP joint of your thumb on the pisiform. Roll the end of your thumb tip in the direction of the 2nd MP joint
- The tip of the thumb lands on the hook of the hamate!

Slide Courtesy of and Property of IAOM-US. www.iaom-us.com

72

Surface Anatomy—volar wrist

- The ulnar nerve and artery travel beneath the hook of the hamate (Guyon's canal)




Guyon's canal/
Ulnar tunnel

Slide Courtesy of and Property of IAOM-US. www.iaom-us.com

73

Surface Anatomy—volar wrist

- Follow the FCR tendon distally to locate the scaphoid tubercle
- This structure is more prominent with radial deviation, due to flexion of the scaphoid (thereby avoiding contact with the radial styloid)




Scaphoid tubercle

Slide Courtesy of and Property of IAOM-US. www.iaom-us.com

74

Surface Anatomy—volar wrist

- The trapezium tubercle is located just distal to the scaphoid tubercle
- Although more difficult to identify, this structure is more prominent with ulnar deviation




Trapezium tubercle

Slide Courtesy of and Property of IAOM-US. www.iaom-us.com

75

Surface Anatomy—volar wrist

- The thick soft tissue on the palm makes finding this landmark more challenging.
- To locate the volar aspect of the trapezoid, first go to the dorsal aspect of the trapezoid, just proximal to the base of the 2nd metacarpal.



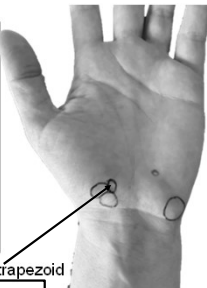
Locating the trapezoid by using dorsal landmarks

Slide Courtesy of and Property of IAOM-US. www.iaom-us.com

76

Surface Anatomy—volar wrist

- The volar aspect of the trapezoid is found just ulnar to the trapezium tubercle.
- Due to its biconcave shape, only a small portion of the trapezoid is present.



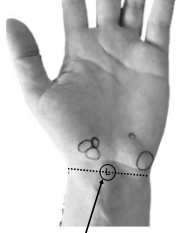
Volar aspect of trapezoid

Slide Courtesy of and Property of IAOM-US. www.iaom-us.com

77

Surface Anatomy—volar wrist

- Draw a line from the radial styloid to the ulnar styloid
- The lunate is located in the center of this line



volar aspect of lunate

Slide Courtesy of and Property of IAOM-US. www.iaom-us.com

Davis A, Wilhelm MP, Pendergrass TJ, et al. Anatomical relationship of palmar carpal bone landmarks used in locating the lunate and capitate during palpation: A cadaveric investigation. J Hand Ther. 2018 July 13.

78

Surface Anatomy—volar wrist

- The capitate is located between the hook of the hamate and the scaphoid tubercle

Slide Courtesy of and Property of IAOM-US. www.iaom-us.com

Davis A. Wilhelm MP, Pendergrass TJ, et al. Anatomical relationship of palmar carpal bone landmarks used in locating the lunate and capitate during palpation: A cadaveric investigation. J Hand Ther. 2018 July 13.

volar aspect of the capitate

79

Wrist Bony Anatomy/Architecture

Image Courtesy of IAOM-US. www.iaom-us.com

80

Image Courtesy of IAOM-US. www.iaom-us.com

81

Image Courtesy of IAOM-US. www.iaom-us.com

82

Radiocarpal Joint—convex/concave

- Roll and slide in opposite directions

Image Courtesy of IAOM-US. www.iaom-us.com

Neumann, 2010

83

Wrist Evaluation

- History
- Inspection
- AROM
- PROM
 - Capsular pattern for radiocarpal joint is equal loss of flexion and extension
 - Capsular pattern for DRUJ is pain at endrange pronation and supination
 - Endfeel for RC and DRUJ is capsuloligamentous
- Resistive Tests
- Special Tests (eg, ballotment tests, synergy test (ECU), ligamentous testing, TFCC provocative testing, scaphoid shift test, midcarpal clunk test)

84

Manual Therapy Techniques

Mobilization techniques for wrist

- Traction
- Glides

Slide Courtesy of and Property of IAOM-US. www.iaom-us.com

85

Joint Mobilization Techniques for the Wrist

Traction

- perpendicular to the treatment plane
- good for pain-relieving techniques
- promotes relaxation in more painful patients

Slide Courtesy of and Property of IAOM-US. www.iaom-us.com

86

Joint Mobilization Techniques for the Wrist

Traction

- Can be used as a warm-up technique, prior to performing glides/slides

Slide Courtesy of and Property of IAOM-US. www.iaom-us.com

87

Joint Mobilization Techniques for the Wrist

Glides

- performed parallel to the treatment plane
- designed to stretch the joint capsule: increases translatory motion
- beneficial for very stiff wrists!

Slide Courtesy of and Property of IAOM-US. www.iaom-us.com

88

Joint Mobilization Techniques for the Wrist

- Mobilizing the **convex** surface on a fixed **concave** surface
- In an **open-chained** manner, used to improve wrist extension at the radiocarpal joint (RCJ)!
- The treatment plane (concave surface) is fixed; therefore, the **mobilization direction does not change!**

Slide Courtesy of and Property of IAOM-US. www.iaom-us.com

89

Joint Specific Techniques

Treatment for RCJ mobility

VOLAR GLIDE: to improve wrist **extension**

Preposition:

- Extension
- Extension + Supination (curved glide)

“ES”

Slide Courtesy of and Property of IAOM-US. www.iaom-us.com

90

Joint Specific Techniques

RCJ VOLAR GLIDE: to improve wrist **extension**




Video demonstration

91

Neuro-muscular re-education

"Gentle Persuasion" to improve wrist **extension**




Video demonstration

92

Joint Specific Techniques: RCJ

Treatment for RCJ mobility

VOLAR GLIDE: to improve wrist **extension**



"ES"

Can perform:

- oscillations
- static holds: 40 seconds x 6 repetitions (for extension preposition only)


Slide Courtesy of and Property of IAOM-US. www.iaom-us.com

93

Joint Specific Techniques: RCJ

To improve wrist flexion:

Dorsal glide of proximal row = Volar glide of distal radius and ulna



Open chain testing = Closed chain treatment

Slide Courtesy of and Property of IAOM-US. www.iaom-us.com

94

Joint Specific Techniques

RCJ VOLAR GLIDE: to improve wrist **flexion**



Video demonstration


95

Joint Specific Techniques: RCJ

Treatment for RCJ mobility

VOLAR GLIDE: to improve wrist **flexion**

Note: open-chain pronation = closed-chain supination!

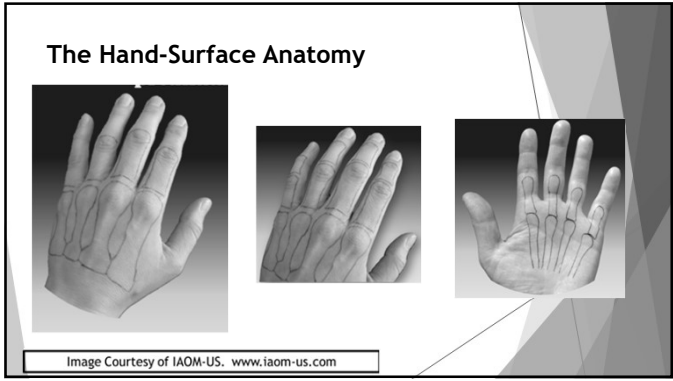


Can perform:

- oscillations
- static holds: 40 seconds x 6 repetitions (for flexion preposition only)

Slide Courtesy of and Property of IAOM-US. www.iaom-us.com

97



98

Hand Evaluation

- ▶ History
- ▶ Inspection
- ▶ AROM
- ▶ PROM
 - ▶ Capsular pattern for MP, PIP and DIP: flexion > extension
- ▶ Resistive Tests
- ▶ Special Tests (eg, ligament stress tests, tendon overload tests)

99

Treatment: Joint Mobilizations

Mobilization techniques

- Traction
- Glides

Slide Courtesy of and Property of IAOM-US. www.iaom-us.com

100

Treatment: Joint mobilization

Traction

- perpendicular to the treatment plane
- Good pain-relieving techniques
- promotes relaxation in more painful patients
- can be used as a warm-up technique, prior to performing glides

Neumann, 2002

Neumann D. Kinesiology of the musculoskeletal system: foundations for physical rehabilitation. St. Louis: Mosby 2002. Slide Courtesy of and Property of IAOM-US. www.iaom-us.com

101

Treatment: Joint mobilization

Glides

- performed parallel to the treatment plane (concavity)
- designed to stretch the joint capsule: increases translatory motion (dominant arthrokinematic component of finger joints)

Slide Courtesy of and Property of IAOM-US. www.iaom-us.com

Neumann D. Kinesiology of the musculoskeletal system: foundations for physical rehabilitation. St. Louis: Mosby 2002.

102

Treatment: Joint mobilization

Glides

Neumann D. Kinesiology of the musculoskeletal system: foundations for physical rehabilitation. St. Louis: Mosby 2002.

Neumann, 2002

Open Chain Mobilizing the concave surface on a fixed convex surface:

- Dorsal glide to improve digital extension
- Volar glide to improve digital flexion

Closed Chain Mobilizing the convex surface on a fixed concave surface (not shown):

- Dorsal glide to improve digital flexion
- Volar glide to improve digital extension

Slide Courtesy of and Property of IAOM-US. www.iaom-us.com

103

Treatment: Joint mobilization

Principles


- Always test the uninvolved side first!
- Purpose of joint mobilization: to improve capsular mobility, thereby increasing ROM
- Traction (perpendicular to joint concavity)
- Glides (parallel to joint concavity): can preposition joint in maximum available flexion or extension
- Joint mobilizations should not be painful!

Slide Courtesy of and Property of IAOM-US. www.iaom-us.com

104

Joint Specific Treatment: Traction

Treatment – MP Traction



Best used for pain management or joint warm up/relaxation


Slide Courtesy of and Property of IAOM-US. www.iaom-us.com

105

Joint Specific Treatment: Traction

Treatment – PIP/DIP Traction

- Pain-relieving technique/warm up/relaxation
- If degenerative changes present at IP joint, use traction only (avoid glides)



Note: beneficial for an "activated arthrosis"!

Slide Courtesy of and Property of IAOM-US. www.iaom-us.com

106

Joint Mobilization Technique: Glide

Glides

- **Open chain:** The treatment plane (concave surface) is mobile; therefore, the mobilization direction adjusts accordingly to remain perpendicular to the phalanx diaphysis!
- **Closed chain:** The treatment plane (concave surface) is fixed; therefore, the mobilization direction does not change throughout the range and remains perpendicular to the phalanx diaphysis!

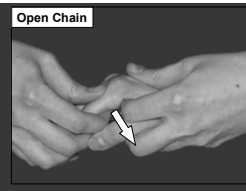
Slide Courtesy of and Property of IAOM-US. www.iaom-us.com

107

Joint Specific Treatment: MP Joint

VOLAR glide to improve FLEXION

Open Chain



Note: The angle of glide changes; remains parallel to the treatment plane

Preposition: Maximal available flexion to increase tension in the dorsal capsule/ lateral bands

Techniques:
-oscillations
-static holds: 40 sec. x 6 repetitions

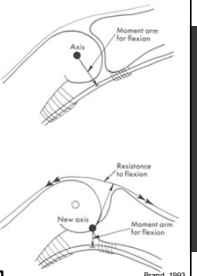
Slide Courtesy of and Property of IAOM-US. www.iaom-us.com

108

Joint Mobilization Technique: Glide

Passive flexion versus volar glide

Demonstrates the **tilt** effect when rotation force is applied as opposed to glide



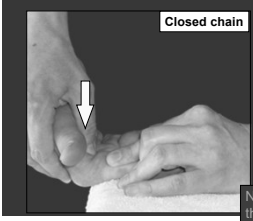
Brand PW, Hollister A. Clinical mechanics of the hand, second edition. St. Louis: Mosby 1993.

Slide Courtesy of and Property of IAOM-US. www.iaom-us.com

109

Joint Specific Treatment: MP Joint

DORSAL glide to improve FLEXION



Closed chain

Preposition:
Maximal available flexion to increase tension in the dorsal capsule/collateral ligaments

Techniques:
Oscillations or static holds:
40 sec. x 6 repetitions

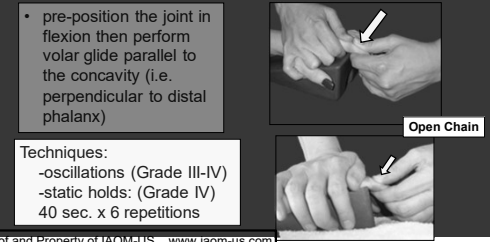
Note: The concavity is immobilized so the angle of glide does not change as the amount of flexion increases.

Slide Courtesy of and Property of IAOM-US. www.iaom-us.com

110

Joint Specific Treatment: PIP/DIP Joints

VOLAR glide to improve FLEXION



• pre-position the joint in flexion then perform volar glide parallel to the concavity (i.e. perpendicular to distal phalanx)

Open Chain


Techniques:
-oscillations (Grade III-IV)
-static holds: (Grade IV)
40 sec. x 6 repetitions

Slide Courtesy of and Property of IAOM-US. www.iaom-us.com

111

Joint Specific Treatment: MP Joint

DORSAL glide to improve EXTENSION



Open Chain

Preposition:
Maximal available extension to increase tension in the volar capsule / volar plate

Techniques:
-oscillations
-static holds: 40 sec. x 6 repetitions

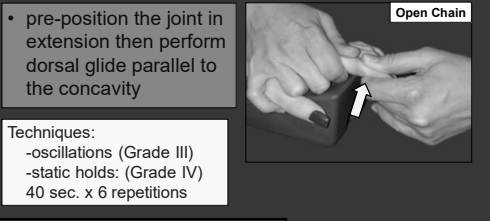
Note: The angle of glide changes; remains parallel to the treatment plane

Slide Courtesy of and Property of IAOM-US. www.iaom-us.com

112

Joint Specific Treatment: PIP Joint

DORSAL glide to improve EXTENSION



• pre-position the joint in extension then perform dorsal glide parallel to the concavity

Open Chain

Techniques:
-oscillations (Grade III)
-static holds: (Grade IV)
40 sec. x 6 repetitions

Slide Courtesy of and Property of IAOM-US. www.iaom-us.com

113

Neuromuscular Re-education

- ▶ Active motion following mobilizations
- ▶ End range isometrics

114

Thank You!

"To be effective, treatment must be an appropriate countermeasure for the condition diagnosed, and this is as much a concern of the doctor as the physiotherapist... the relationship between physician and physiotherapist becomes complimentary. Between the two of them, nearly all patients can be dealt ..."

-JamesCyriax

Emily Altman
altman@hss.edu

115

115